

**Experience of using cryo methods
in oncodermatology and cosmetology**

**Kachalova O.
Zavadaska T.**

Kyiv-2016

Recommended Cryosurgical Techniques for:

- **Actinic keratosis**
 - **solar lentigo**
 - **seborheic keratosis**
 - **viral wart**
 - **molluscum contagiosum**
 - **Dermatofibroma**
 - **Cherry angioma**
- **Common warts**
- **Cutaneous horn**

- **Hypertrophic scar**
 - **Keloid**
 - **Myxoid cyst**
 - **Oral mucocele**
 - **Pyogenic granuloma**
 - **Sebaceous hyperplasia**
- **Skin tags**

- **Solar lentigo**
- **Ingrown toenail**

Advantages of cryosurgery

- ›requires little time and fits easily
- ›treatment include a short preparation time, low risk of infection, and minimal wound care
- ›requires no expensive supplies or injectable anesthesia, and the patient does not have to return for suture removal.
- ›Less invasive than surgery, involving only a small incision
- ›Complications (pain, bleeding) of surgery are minimized
- ›less expensive than other treatments
- ›shorter recovery time
- ›can be done without ant or using only local anesthesia.
- ›treatment on a limited area, can avoid the destruction of nearby healthy tissue
- ›treatment can be safely repeated
- ›may be used along with standard treatments

Disadvantages

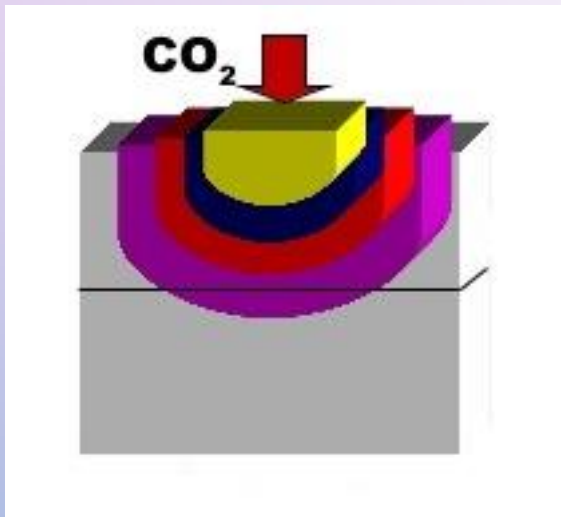
- uncertainty surrounding its long-term effectiveness
- Potential side effects include bleeding, blister formation, headache, hair loss, and hypopigmentation, if nerves are damaged, loss of sensation may occur, but rarely scarring.
- Skin lesions often can be treated in a single session, although some require several treatments.
- Cryosurgery does have side effects, although they may be less severe than those associated with surgery or radiation therapy.







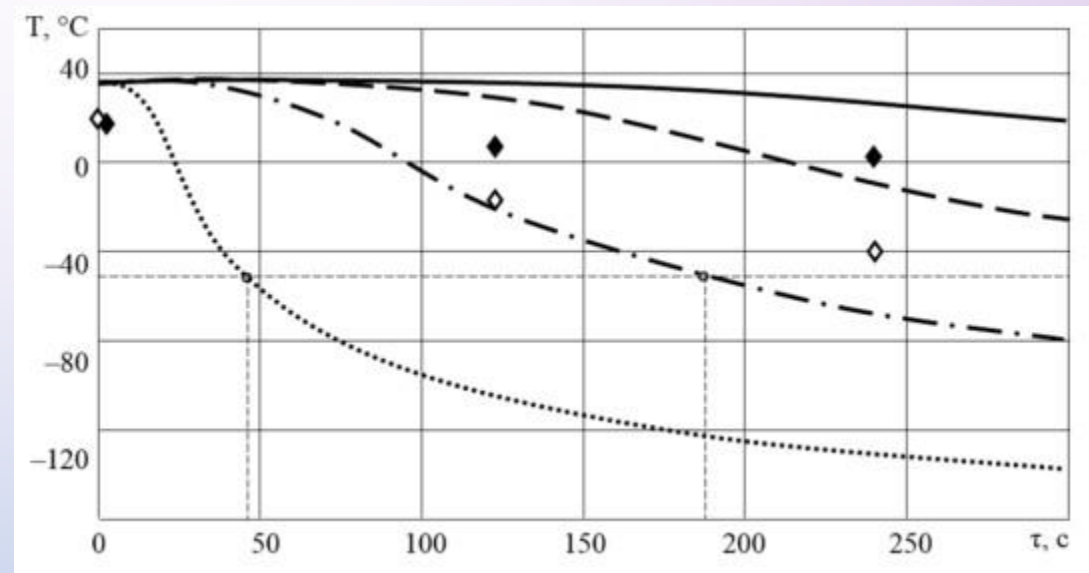
Cryotherapy as a selection method for treatment skin metastasis

Patient, 35 year old. DS.: C-r glandule mamma dextra (T3N2M1). Operation – mastectomia dextra (Breast Cancer Treatment Protocol). Multiple Skin metastasis localized on breast and back. Size of metastasis 1,0-2,0 cm. We Combine CO2-Laser ablation with cryosurgery (exposition time 15-20 seconds, repeat 3 times). Than was forming a dry scabs with next scab rejection on 10-14 day. After this treatment metastasis $>1,5$ cm stopped prolongation, metastasis $<1,5$ cm in the 30% -replaced. Remission – 6 mounts after therapy.

impact of the methods on biological tissues



-  Ablation
-  Necrosis 20-50 μm
-  Coagulation 100-200 μm
-  Hyperthermia 200-500 μm



Calculated temperature field of cryo in biological objects

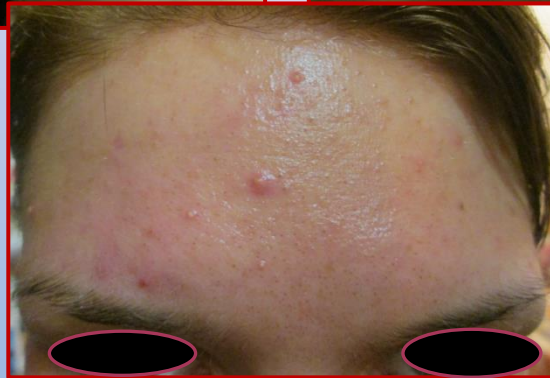
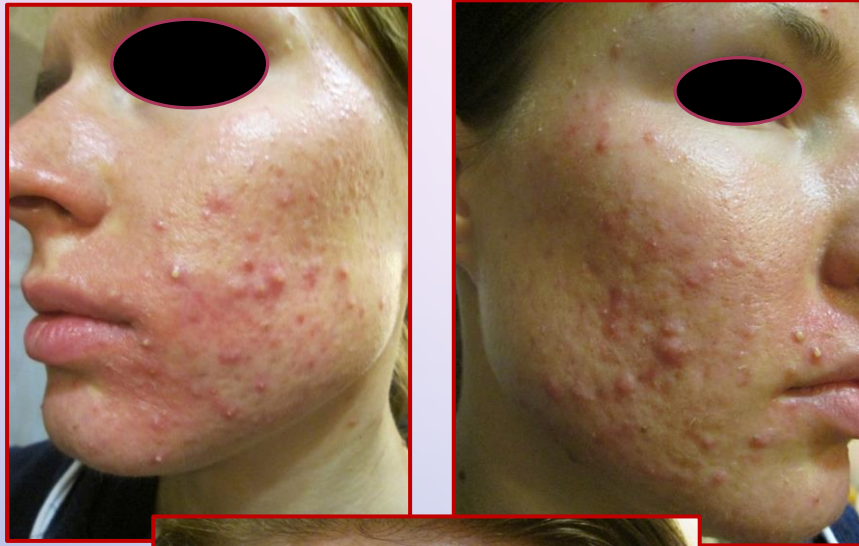


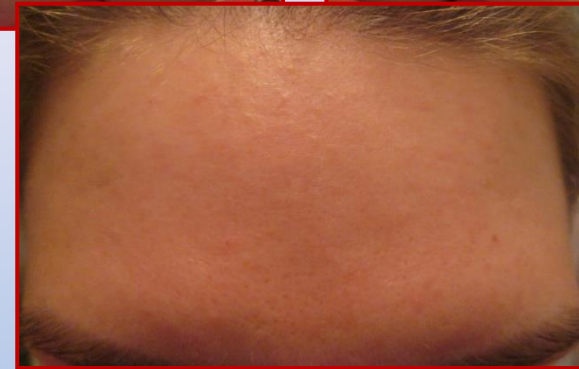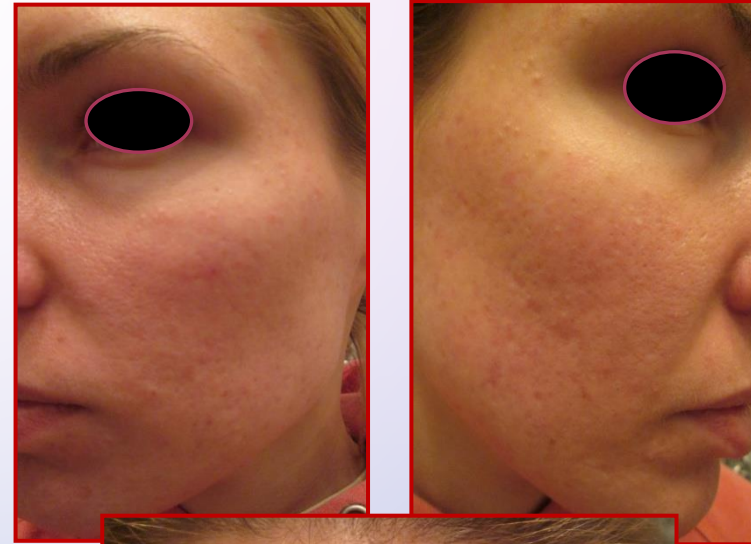
DS.: *Acne Vulgaris, Severe acne*

Oral therapies : treatment of gastro duodenal disorders and hormones

Topical treatment: photodynamic therapy (PDT) with 5-Aminolevulinic acid (5-Ala) + Cryotherapy



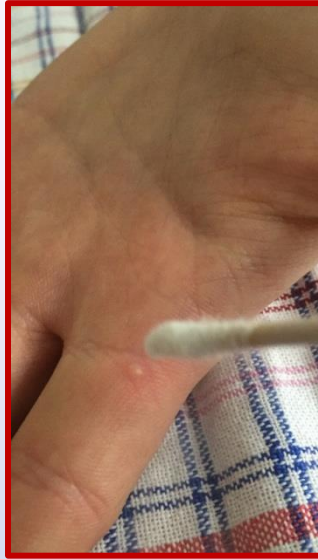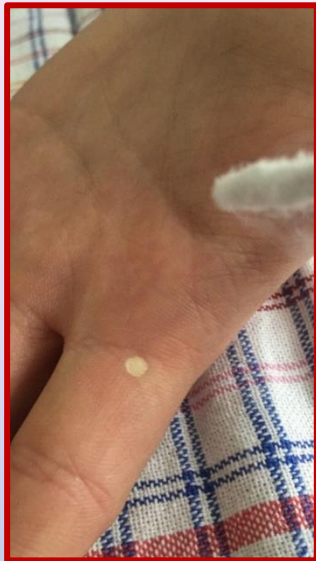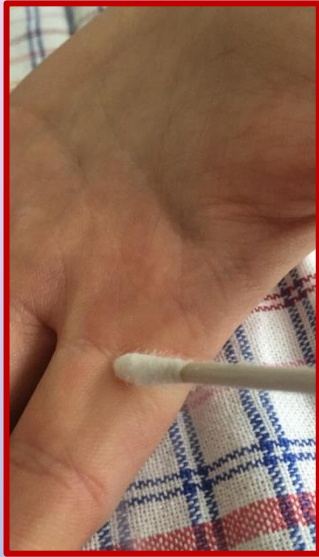Before



After



Cryotherapy of viral wart



Right palm

Cryo therapy with liquid nitrogen every two weeks until the wart has gone (up to four months) may be effective. Liquid nitrogen is applied until a ring of frozen tissue is visible around the wart, typically 5-30 seconds.

Thank you for attention

